



## A Case Report on Retained Surgical Mop in Abdomen- Endoscopic Extraction

Md. Ariful Alam<sup>1\*</sup>, Md. Habibullah Sarkar<sup>2</sup>, Md. Baharul Islam<sup>2</sup>, Asim Sarkar<sup>3</sup>, Most Tanzilal Lisha<sup>4</sup>, Chandan Kumar Kundu<sup>5</sup>

<sup>1</sup>Associate Professor, Colorectal Surgery. Department of Surgery, Rajshahi Medical College Hospital, Rajshahi, Bangladesh

<sup>2</sup>Professor, Department of Surgery, Rajshahi Medical College Hospital, Rajshahi, Bangladesh

<sup>3</sup>Consultant, Colorectal Surgery. Department of Surgery, Rajshahi Medical College Hospital, Rajshahi, Bangladesh

<sup>4</sup>FCPS Trainee. Department of Surgery, Rajshahi Medical College Hospital, Rajshahi, Bangladesh

<sup>5</sup>MS Resident. Department of Surgery, Rajshahi Medical College Hospital, Rajshahi, Bangladesh

**Abstract:** Surgical mop retained in the abdominal cavity following surgery is a serious but avoidable complication. The condition may manifest either as an exudative inflammatory reaction with formation of abscess, or aseptically with a fibrotic reaction developing into a mass. This case report documents the successful extraction of a retained surgical mop from duodenum in a 50 years old lady, who presented with features of gastric outlet obstruction 11 months following open cholecystectomy. This case underscores the importance of vigilance for gossypiboma in post-operative patients and highlights endoscopy as a valuable diagnostic and therapeutic tool which can avoid invasive surgical interventions.

**Keywords:** Gossypiboma, Endoscopic extraction, GOO, Post-operative complication.

### Case Report

#### \*Correspondence:

**Dr. Md. Ariful Alam**

Associate Professor, Colorectal Surgery,  
Department of Surgery,  
Rajshahi Medical College Hospital  
Rajshahi, Bangladesh  
Email: [aariful85@gmail.com](mailto:aariful85@gmail.com)

#### How to cite this article:

Alam MA, Sarkar MH, Islam MB, Sarkar A, Lisha MT, Kundu CK; A Case Report on Retained Surgical Mop in Abdomen- Endoscopic Extraction. *Taj* 2024;37 (1): 182-186.

#### Article history:

Received: December 10, 2023

Revised: January 25, 2024

Accepted: February 28, 2024

Published: April 27, 2024

### Article at a glance:

**Study Purpose:** To report a case of successful endoscopic extraction of a retained surgical mop in the abdomen and emphasize the importance of being aware of gossypiboma in post-operative patients.

**Key findings:** A 50-year-old woman presented with gastric outlet obstruction 11 months after cholecystectomy. Imaging revealed a mass in the duodenum, diagnosed as gossypiboma. Endoscopic removal of the surgical mop was successful.

**Newer findings:** This case demonstrates the effectiveness of endoscopy in managing gossypiboma, avoiding the need for more invasive surgery.

**Abbreviations:** GOO: Gastric Outlet Obstruction RMCH: Rajshahi Medical College Hospital USG: Ultrasonography CT: Computed Tomography GIT: Gastrointestinal Tract.



Copyright: © 2024 by the authors. This is an open-access article distributed under the terms of the Creative Commons Attribution 4.0 International License (CC BY-NC 4.0) which permits unrestricted use, distribution, and reproduction in any medium for non-commercial use provided the original author and source are credited.

## INTRODUCTION

Gossypiboma refers to a surgical complication where a surgical mop or cotton material is accidentally left inside a patient's body after a surgical procedure. The term comes from "Gossypium," which is the genus for cotton and "Boma," a Swahili word meaning a concealed or

hidden place. Other terms used include "Textile" and "Glaucoma". This rare occurrence can lead to complications if the retained material is not discovered and removed promptly. Intraluminal migration is relatively rare, leading to obstruction. Patients develop symptoms of abdominal pain, nausea, vomiting, anorexia, and weight loss resulting from obstruction or a malabsorption type

**Peer Review Process:** The Journal "The Journal of Teachers Association" abides by a double-blind peer review process such that the journal does not disclose the identity of the reviewer(s) to the author(s) and does not disclose the identity of the author(s) to the reviewer(s).

syndrome caused by the multiple intestinal fistulas or intraluminal bacterial overgrowth.<sup>1</sup> Early recognition of this entity will ensure prompt institution of appropriate treatment, reducing morbidity and mortality in such patients.<sup>2</sup>

### CASE PRESENTATION

A 50-years old gentle lady, admitted in RMCH with history of open cholecystectomy 11 months back. Her post operative period was

uneventful and was discharged as usual. She was well for a reasonable period and resumed her daily activities. After 8 months of cholecystectomy, she developed constant, dull aching epigastric pain having no aggravating or relieving factors. She also complained of early satiety and fullness after taking meal for last 1 month which was relieved by vomiting. Vomitus was bilious, foul smelling containing partially digested food materials which she recently ingested. She felt hungry after vomiting.

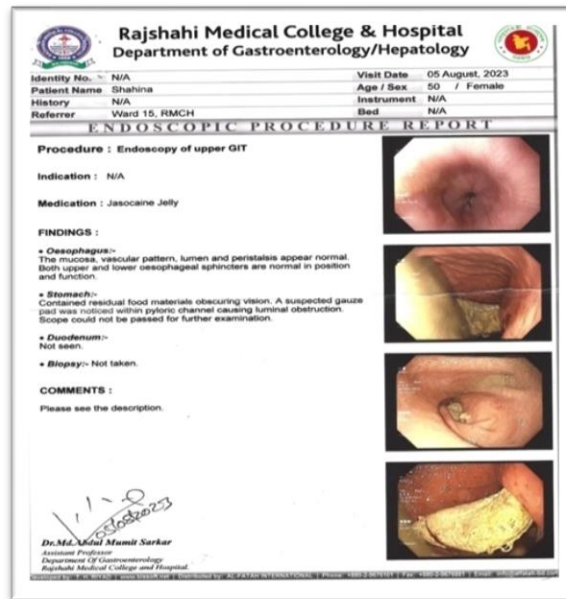


Figure 1: Upper GI endoscopy surgical mop clearly visualized protruding through the pyloric opening

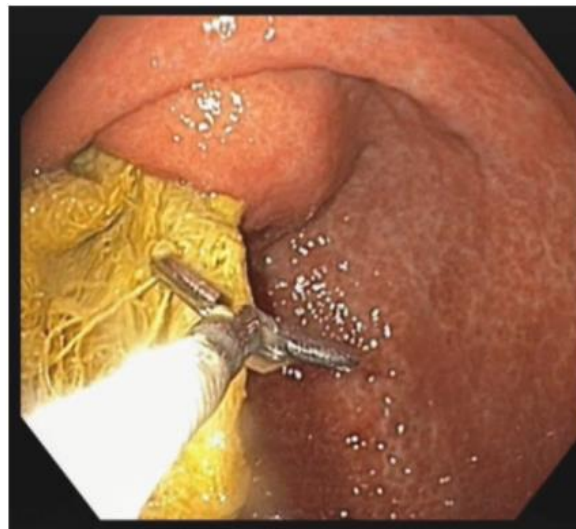

Figure 2: Endoscopic removal of surgical mop

She also complained of occasional feverishness for last one month. She was mildly anemic and dehydrated. All other vital parameters

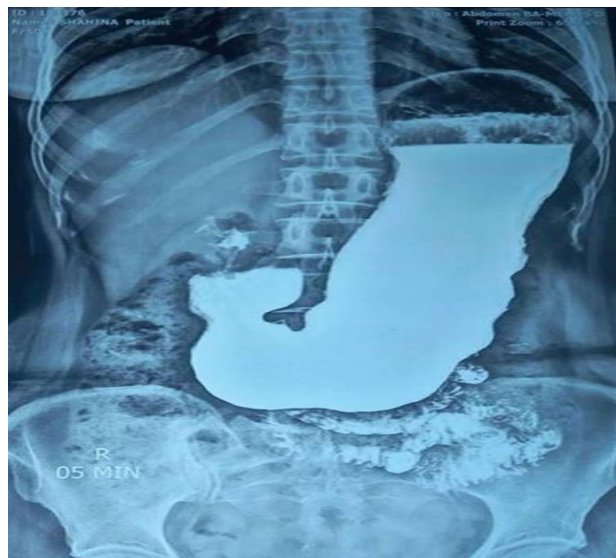were within normal limit. A well healed right subcostal surgical scar mark was present with mild tenderness over right hypochondriac region. No

obvious lump felt on abdominal palpation. USG of abdomen demonstrated thick-walled gut

measuring about 8.2 x 6.2 cm in right hypochondrium suggestive of GIT mass.



**Figure 3: Surgical mop after removed from duodenum**



**Figure 4: Barium meal x-ray after 3 days of intervention**

In view of the sonographic finding, she underwent a contrast enhanced abdominal CT scan which revealed Gossypiboma in the lumen of pyloric canal extending within the duodenum measuring about 7.5 x 7.0 cm, causing partial luminal obstruction (D/D: Bezoar). Then Upper GI

endoscopy was carried out, where surgical mop was clearly visualized protruding through the pyloric opening, it was not possible to negotiate the scope further despite repeated attempts strongly suggesting outlet obstruction.

## DISCUSSION

Abdominal gossypiboma is an iatrogenic postoperative complication resulting in surgical mop forgotten in the abdominal cavity during surgery. It has become very rare as safety rules in the operating room follow precise guidelines. However, it must be suspected when there is pain,

abdominal mass or signs of infection in patients with a history of abdominal surgery.<sup>3</sup> The time to diagnosis of gossypiboma varies from few days to many years after surgery. It could then lead to intra-abdominal abscess formation and necrosis of the intestinal wall can occur as a result of the pressure and irritation on the digestive tract and fistula

occurs when the foreign body erodes into the lumen. Like our patient in whom the forgotten surgical mop result in as a mass which simulate a tumor in epigastrium and causes gastric outlet obstruction.

The clinical presentation may be nonspecific depending on the exact site where the retained surgical mop is located.<sup>4</sup> It can remain asymptomatic. In the case of migration of the item into the lumen of the stomach, small intestine or colon, the patient would present nausea, vomiting or any kind of abdominal discomfort. The multiple intestinal fistulas or intraluminal bacterial overgrowth lead into a malabsorption syndrome with weight loss. Bowel obstruction can also happen. In our patient, the gossypiboma migrated into the duodenum extended upto pyloric canal causing gastric outlet obstruction. Diagnosis is difficult to establish as it can mimic hematoma, abscess, granulomatous process or even a cystic mass or a neoplasm. On ultrasonography, a gossypiboma is usually visualized as a well-defined mass with wavy internal echogenic structure showing posterior acoustic shadowing.<sup>5</sup>

The CT scan is the modality of choice to diagnose abdominal textile. The pathognomonic characteristic feature is spongiform or mottled pattern due to air bubbling. Other suggestive feature is a well-defined mass with a dense enhanced capsule and variable density and calcification.<sup>6</sup> Usually, open surgery has been the mainstay method for textile removal.<sup>7</sup> Few cases have been reported in relation with removal of retained gauze by upper gastrointestinal endoscopy. The first case was reported in 2009 by Mefire, A., *et al.*, where a 20 cm × 20 cm surgical sponge was endoscopically removed.<sup>8</sup> In our patient, gossypiboma was successfully removed by upper GI endoscopy with an intact specimen. Prognosis is excellent if gossypiboma is removed early after diagnosis. However, when diagnosis and treatment are delayed, mortality rates varies between 10 and 17%.<sup>9</sup> To our knowledge this is the first case report in Bangladesh of a large surgical mop of upper GIT that successfully removed endoscopically.

We report this case because of its large size (24cm x 20cm) and minimally invasive removal by

endoscopy without any anesthesia or even any sedation though anesthetics and surgical team were ready in operating room to combat any unwanted events. We performed it successfully without any complications. After the procedure patient was kept nil by mouth and on 3rd day a post procedure barium study was performed which exclude any leakage or fistulation. News tools as bar codes automated counting systems and counters, radiofrequency labeled sponges and radio frequency readers can avoid manual errors in counting.<sup>10</sup> Indeed, the use of sponges impregnated with radio-opaque substances with an intraoperative abdominal radiograph just before the closure can help detecting a foreign body.<sup>11</sup> An excellent communication between the surgical team, operating room nurses and anesthetists is mandatory to reduce the incidence of abdominal textile.

## CONCLUSION

Abdominal gossypiboma is an avoidable postoperative complication which has devastating consequences on the patient and medico legal implications to the surgeons. This case highlights the need for ongoing awareness and vigilance regarding gossypiboma in the postoperative period. Endoscopic removal, as demonstrated in this case, represents a safe and effective alternative to traditional surgical approaches which can facilitate its management and could avoid a second major surgical procedure. However, prevention remains the best tool.

## Recommendations

- Maintain high awareness to prevent retained surgical items, using technology and thorough counts.
- Regularly review surgical practices to identify and address gaps.
- Provide ongoing training on counting techniques and signs of retained items for surgical teams.

## Author Contributions

In the study, Dr. Md. Ariful Alam likely led the conception, design, data analysis, drafting, and final approval. Professor Dr. Md. Habibullah Sarkar probably contributed to conception, data interpretation, critical revision, and final approval. Professor Dr. Md. Baharul Islam likely participated

in data acquisition, analysis, critical revision, and final approval. Dr. Asim Sarkar probably contributed to data analysis, interpretation, critical revision, and final approval. Dr. Tanzil Lisha likely assisted with data acquisition, drafting, and final approval. Dr. Chandan Kumar Kundu probably contributed to data analysis, interpretation, critical revision, and final approval.

**Funding:** No funding sources

**Conflict of interest:** None declared

## REFERENCE

1. Patil KK, Patil SK, Gorad KP, Panchal AH, Arora SS, Gautam RP. Intraluminal migration of surgical sponge: gossypiboma. *Saudi Journal of Gastroenterology*. 2010 Jul 1;16(3):221-2.
2. Agrawal H, Gupta N, Krishengowda U, Gupta AK, Naskar D, Durga CK. Transmural migration of gossypiboma: a rare cause of acute abdomen. *Indian Journal of Surgery*. 2018 Feb;80:84-6.
3. Ogundiran T, Ayandipo O, Adeniji-Sofoluwe A, Ogun G, Oyewole O, Ademola A. Gossypiboma: complete transmural migration of retained surgical sponge causing small bowel obstruction. *Case Reports*. 2011 Jun 30;2011:bcr0420114073.
4. Kansakar R, Thapa P, Adhikari S. Intraluminal migration of Gossypiboma without intestinal obstruction for fourteen years. *JNMA; Journal of the Nepal Medical Association*. 2008 Jul 1;47(171):136-8.
5. Obeidat KA, Aleshawi AJ, Alebbini MM, Bani Yasin SN. Abdominal intraluminal gossypiboma: demographics, predictors of intraluminal site, diagnostic and treatment measures. *Clinical and experimental gastroenterology*. 2020 Feb 27;65-72.
6. Sozutek A, Yormaz S, Kupeli H, Saban B. Transgastric migration of gossypiboma remedied with endoscopic removal: a case report. *BMC Research notes*. 2013 Dec;6:1-4.
7. Zantvoord Y, van der Weiden RM, van Hooff MH. Transmural migration of retained surgical sponges: a systematic review. *Obstetrical & gynecological survey*. 2008 Jul 1;63(7):465-71.
8. Mefire A, Tchounzou R, Guifo ML, Fokou M, Pagbe JJ, Essomba A, Malonga EE. Retained sponge after abdominal surgery: experience from a third world country. *Pan African Medical Journal*. 2009;2(1).
9. Wig JD, Goenka MK, Suri S, Sudhakar PJ, Vaiphei K. Retained surgical sponge: an unusual cause of intestinal obstruction. *Journal of clinical gastroenterology*. 1997 Jan 1;24(1):57-8.
10. Greenberg CC, Diaz-Flores R, Lipsitz SR, Regenbogen SE, Mulholland L, Mearn F, Rao S, Toidze T, Gawande AA. Bar-coding surgical sponges to improve safety: a randomized controlled trial.
11. Zejnullahu VA, Bicaj BX, Zejnullahu VA, Hamza AR. Retained surgical foreign bodies after surgery. *Open access Macedonian journal of medical sciences*. 2017 Feb 2;5(1):97.

**The Journal of Teachers Association**

*Abbreviated Key Title: TAJ*

*Official Journal of Teachers Association Rajshahi Medical College*



**Publish your next article in TAJ**

For submission scan the QR code

E-mail submission to: [tajrnc8555@gmail.com](mailto:tajrnc8555@gmail.com)