

**Original Article****V-Y Rotation Advancement Flap for Sacral Sore: Experiences at Rajshahi**Afroza Nazneen,¹ Md. Nafis Alam Adnan²**Abstract**

Grade III and Grade IV sacral pressure sores are required surgical closure. The gluteal fascio-cutaneous rotation advancement flap with V-Y closure was performed in our hospital on 50 cases of sacral sore from 2017 to 2019. The largest defects closed with a unilateral flap were up to 14 cm, and a bilateral flap needed to close 15-22 cm in diameter. In 1.5 to 24 months of follow-up time, none of the patients developed wound dehiscence or flap necrosis requiring repeated surgery. The V-Y rotation advancement flap technique is simple, can be performed quickly, has minimal associated morbidity, and has a good outcome. Furthermore, we can use the same flap design in recurrent cases.

Keywords: Sacral sore, V-Y Rotation Advancement flap.

TAJ 2022; 35: No-1: 33-38

Introduction

Pressure sores usually develop due to prolonged tissue ischemia and insufficient mobilization over a bony prominence. They typically develop secondary to a medical problem that necessitates extended bed rest. The sacral region is one of the most common locations for such wounds, and surgical methods are needed when conservative measures fail, usually in Grade III and Grade IV cases. Local flaps in the gluteal region are typically preferred. Here we used the gluteal fasciocutaneous rotation advancement flap with V-Y closure (Fig.1) to manage sacral pressure sores in 50 patients. The design combined the classic rotation and V-Y advancement flap patterns. When the wound was closed, the tension at the distal end of the rotation flap was relieved by flap advancement, and the combined rotation-advancement action was supported laterally with V-Y closure. A broad skin pedicle

was preserved at the inferomedial part of the flap. This pedicle augmented the blood supply to the flap skin and kept the surgical incision small, thus helping to reduce the risk of fecal contamination and associated wound-healing problems. The largest defects closed with a unilateral rotation-advancement flap and bilateral rotation-advancement flaps were 14 and 22 cm in diameter, respectively. In 1.5 to 24 months of follow-up, none of the patients developed wound dehiscence or flap necrosis requiring repeated surgery. This technique is simple, can be performed quickly, has minimal associated morbidity, and yields a good outcome.

Materials and Methods

Between 2017 and 2019, we managed 50 patients (43 male, 07female) using gluteal fasciocutaneous rotation advancement flaps with V-Y closure. The patients ranged in age

¹ Associate Professor & Head, Department of Burn and Plastic Surgery, Rajshahi Medical College

² Medical Officer, Department of Burn and Plastic Surgery, Rajshahi Medical College Hospital

from 22 to 90 years and the most common reason for prolonged paraplegia was falling from height. Among them, 16 were the patients with CVD, 6 of them due to road traffic accidents, 3 of them due to spine TB, and 2 of them due to prolonged postoperative hospital stay. Among the total population, 28 of these individuals had paraplegia, 45 were quadriplegic, and 17 were hemiplegic. In 21 patients with no trauma cases, senility accompanied by diabetes mellitus and chronic renal failure were the reasons for extended bed confinement. All the patients had stage IV decubitus ulcers. The sores ranged in size from 8 to 22 cm in diameter. 43 ulcers (ranging in size from 8 to 14 cm) were reconstructed with unilateral flaps, and seven ulcers that ranged from 15 to 22 cm were reconstructed with bilateral flaps.

Operative Technique

The first step was to excise the ulcer, underlying bursa, and involved bone. Adequate haemostasis is compulsory.⁶ In our experience, a flap raised on one side was sufficient to close defects up to 14 cm in diameter. In larger defects than this, or in cases in which closure of the unilateral flap could only be achieved under tension, bilateral flaps were elevated. The flap was initially drawn in the same pattern used to create gluteal fasciocutaneous V-Y advancement flaps. The incisions were given with caution, better to preserve both the Superior and Inferior Gluteal arteries. Each arm of the V was curved in a slightly convex form to include more cutaneous perforating vessels in the flap and to enable smooth rotational movement (Fig. 1). The first incision was made on the upper side of the triangle. The lateral extent of this incision was directed to the lower side of the triangular flap as much as necessary to enable tension-free wound closure when the flap was

Results

All the wounds were reconstructed successfully. Among all 50 patients, 12 developed marginal (2-4mm) flap necrosis at

rotated and advanced toward the defect. The elasticity and redundancy of the tissues in the gluteal region were also crucial for achieving optimal wound closure. The fascia under the skin bridge was cut with scissors (Fig. 1, center). The donor area was closed with V-Y closure, which supported and pushed the flap from behind. It is very important to reinforce the wound edges with subcutaneous absorbable sutures in the dermis, followed by skin sutures. Two negative suction drains were used routinely in all the cases and kept in situ for up to 14 days. And the stitches are removed on the 14th postoperative day. The patients are suggested to avoid the supine position.

crescent

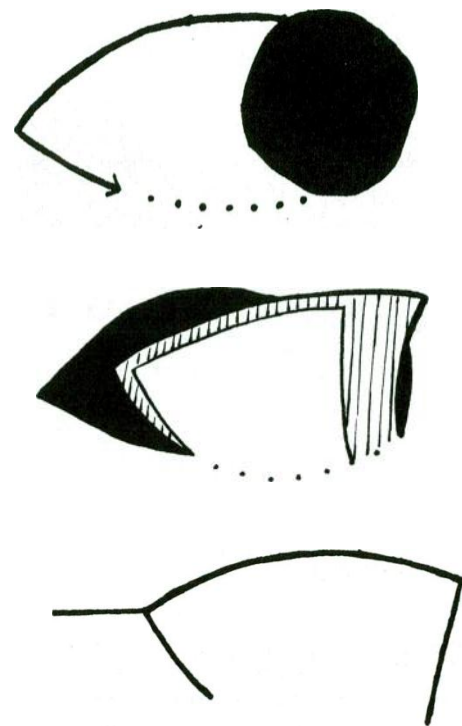


FIG. 1. An illustration of Rotation Advancement Flap. Supported laterally with V-Y closure.

the corner of the vertical and horizontal limb of 'Y,' healed without surgical intervention. As we kept the drains for two weeks, none of the cases had seroma-related complications. Within this 24months follow-

up time, only 04 patients came next with recurrent sacral sore, and we did the same flap from the opposite side successfully.

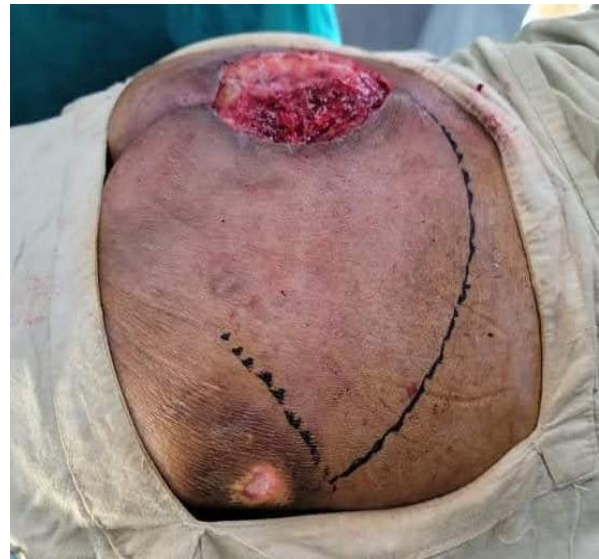
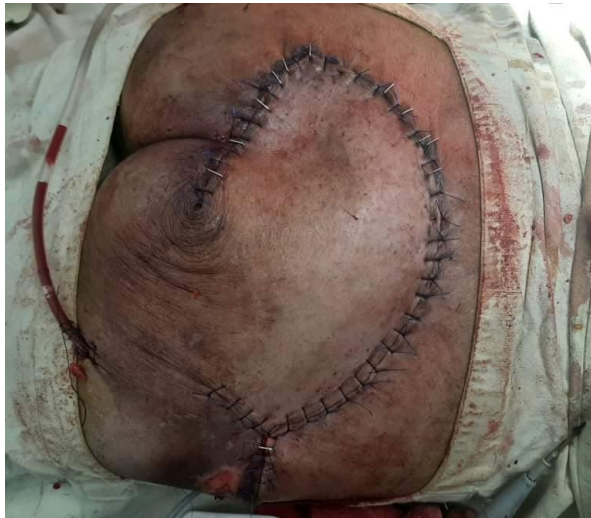
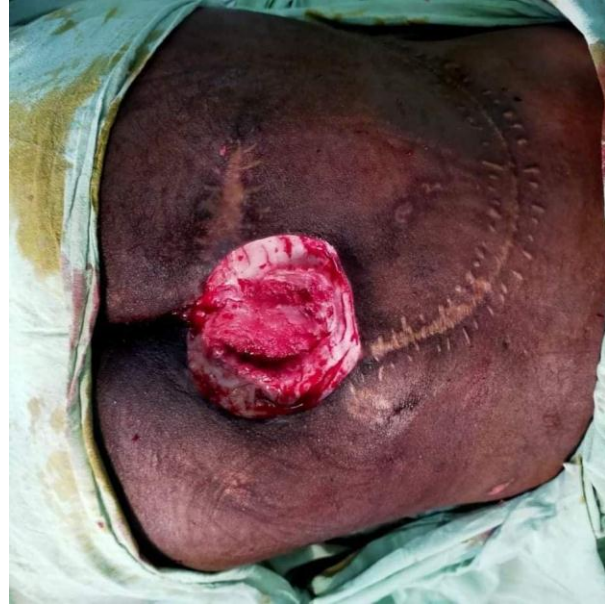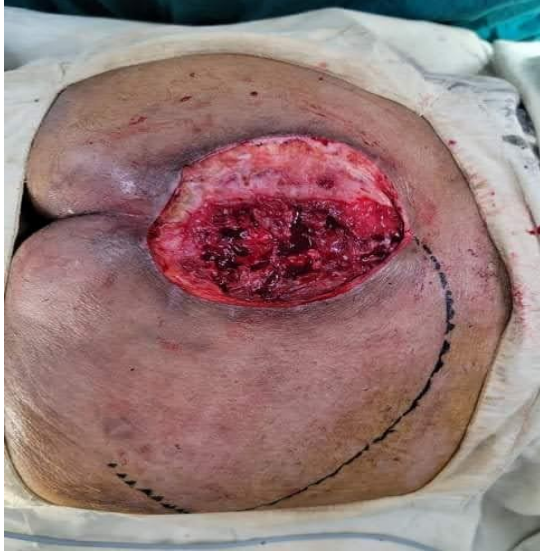Fig. 2. Preoperative appearance of a sacral pressure sore. A wide surgical wound is created after debridement. (*above*) The appearance of the reconstructed gluteal region per-operative pictures. (*below*). Unilateral Flap coverage. Crescent-shaped, fascio-cutaneous flaps in an interdigitating manner to cover defects that were

as large as 20 cm and 22 cm in diameter. The largest defect we closed with a unilateral rotation-advancement flap was 14 cm in diameter, and the largest defect that we closed with bilateral flaps was 22 cm in diameter.

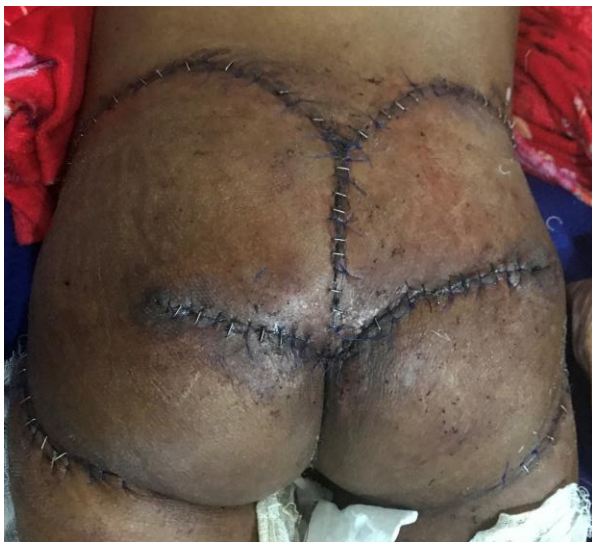
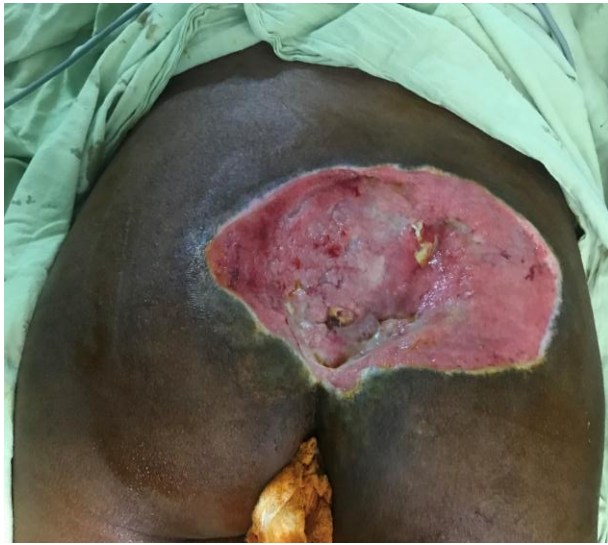
Fig. 3. Preoperative appearance of a sizeable sacral sore. (*above*) The appearance of the reconstructed gluteal region per operative pictures. (*below*) Reconstructed by Bilateral V-Y Rotation Advancement flap.

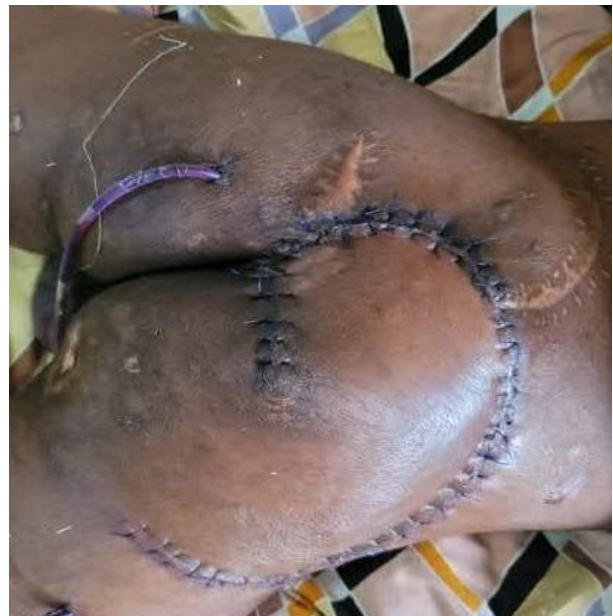As our experience and other reports demonstrate, various modifications of the

gluteal fasciocutaneous flap can be used to close defects of similar dimensions.

The gluteal fasciocutaneous rotation-advancement flap technique requires a smaller incision than the classic V-Y advancement flap. This is advantageous for bedridden patients because it is difficult to protect wounds in such a setting. In addition, one report noted that preserving a narrow skin bridge near the anus in a musculocutaneous flap helped to reduce the risk of maceration, fecal contamination, and associated wound-healing problems.¹³ In our patients, using a fasciocutaneous rotation-advancement flap with a comprehensive skin bridge yielded both benefits.

In terms of other advantages, we think that.

Fig. 4. A recurrent pressure sore (*Above*), Previously covered by a left-sided V-Y Rotation



Advancement flap. Later on, covered by Right sided flap. (*Below*)

adding a skin pedicle to the flap augments the vascularity of the flap skin. Also, this flap design is superior to the plain rotation flap because the tension at the distal end of the rotation flap is relieved by advancement, and the combined action of rotation-advancement is supported laterally with V-Y closure. Furthermore, the required advancement distance was reduced when

advancement was combined with a rotation action. Finally, we observed that a complete incision of the triangular gluteal fasciocutaneous V-Y advancement flap was not usually necessary because flap tissue tends to be lax at the inferomedial aspect near the anal region.

In conclusion, our experience has shown that this flap technique is simple and can be performed quickly. When used in appropriate cases, there is minimal morbidity, and the outcome is highly successful. As recurrence of sacral sore is more in these bedridden patients, we can reuse the same flap for the newer one. (Fig. 4)

Discussion

Local flaps in the gluteal region are always preferable for sacral pressure sore coverage. Various gluteal fasciocutaneous and musculocutaneous flaps are commonly used for Grade iv Sacral sore.¹⁻⁵ The gluteal fasciocutaneous V-Y Rotation advancement flap is a method that other authors and we have preferred for the management of these ulcers.^{1-3,14} Use of this type of flap conserves the gluteus maximus muscle and does not preclude ambulation in a mobile patient. Fascio cutaneous flaps, which are less sensitive to ischemia and more resistant to pressure than muscle flaps, have high mechanical resistance. Blood loss is reduced, and the percentage of pressure sore-free survival is increased when fasciocutaneous flaps are used.^{2,3,6} Although these advantages are important, we think that flap choice should be decided on a case-by-case basis, according to specific indications. A musculocutaneous flap may be more appropriate for a large, deep ulcer with exposed underlying bone or joint, as other authors have suggested.⁵⁻⁹ If the subcutaneous tissue loss beyond the wound periphery is extensive, then it is difficult to obliterate the dead space with a fascio cutaneous flap. If the subcutaneous tissue loss is minimal, then a fascio cutaneous flap will fill the ulcer defect well in most cases. Unilateral rotation

advancement fasciocutaneous flaps can be used to close defects up to 14 cm in diameter. If the wound is larger or a unilateral flap would have to be closed under tension, bilateral flaps are indicated. If more elasticity or mobility of bilateral or unilateral flaps is required for closure of extensive and deep ulcers, the design can be easily converted to any unlayered or multilayered musculocutaneous V-Y advancement flap.^{9,10} The largest defects that were closed with unilateral and bilateral modified gluteal fascio-cutaneous V-Y advancement flaps were 12 X 12 cm and 15 X 21 cm, respectively, in the series of Ohjimi et al.² Akan et al.^{11,12} described approximating bilateral,

Conclusion

To our knowledge, this is the first study focusing on the region where the alleged rape cases have occurred in the Rajshahi district. The corresponding social workers may consider this study the baseline information and will take proper initiative to stop or minimize rape-like heinous incidence in Rajshahi.

Conflict of interest: None declared

References

1. Park, C., and Park, B. Y. Fasciocutaneous V-Y advancement flap for repair of sacral defects. *Ann. Plast. Surg.* 1988;21: 23.
2. Ohjimi, H., Ogata, K., Setsu, Y., and Haraga, I. Modification of the gluteus maximus V-Y advancement flap for sacral ulcers: The gluteal fasciocutaneous flap method. *Plast. Reconstr. Swg.* 1996; 98: 1247.
3. Yamamoto, Y., Tsutsumida, A., Murazumi, M., and Sugi-hara, T. Long-term outcome of pressure sores treated with flap coverage. *Plast. Reconstr. Surg.* 1997;100: 1212.
4. Fisher, J. Arnold, P. G., Waldorf, J and Woods, J E. The gluteus maximus musculocutaneous V-Y advancement flap for large sacral defects. *Ann. Plast. Surg.* 1983; 11: 517.
5. Rubayi, S., and Doyle, B. S. The gluteus maximus muscle-splitting myocutaneous flap for treatment of sacral and coccygeal pressure ulcers. *Plast. Reconstr. Surg.* 1995; 96: 1566.
6. Wechselberger, G., Schoeller, T., and Otto, A. Principles in the operative treatment of pressure sores. *Arch. Surg.* 1998; 133: 465.

7. Baran, C. N., Celebioglu, S., Civelek, B., and Sensoz, O. Tangentially split gluteus maximus myocutaneous island flap based on perforator arteries for the reconstruction of pressure sores. *Plast. Reconstr. Surg.*, 1999; 103: 2071.
8. Gould, W. L., Montero, N., Cukic, J., Hagerty, R. C., and Hester, T. R. The "split" gluteus maximus musculocutaneous flap, 1994; *Plast. Reconstr. Surg.* 93: 330.

All correspondence to
Dr. Afroza Nazneen
Associate Professor and Head,
Department of Burn and Plastic Surgery,
Rajshahi Medical College
Email: drafrozaasha@yahoo.com